AMBOSS

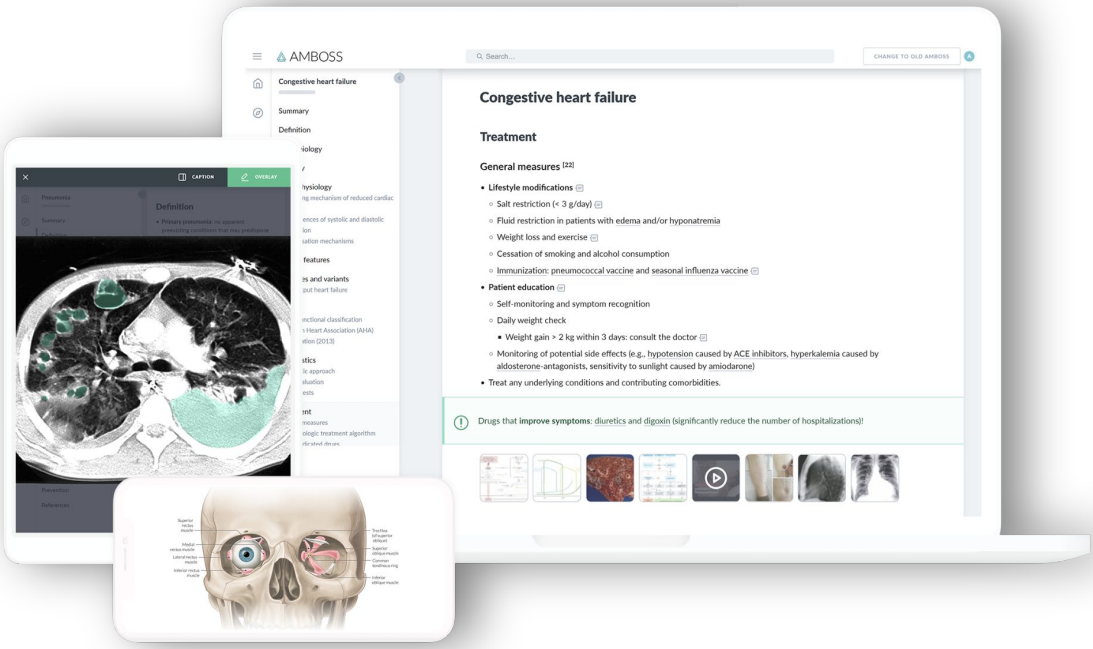
AMBOSS
Search...
CHANGE TO OLD AMBOSS
Congestive heart failure
Summary
Definition
Congestive heart failure
Treatment
General measures [22]
Lifestyle modifications
Salt restriction (< 3 g/day)
Fluid restriction in patients with edema and/or hyponatremia
Weight loss and exercise
Cessation of smoking and alcohol consumption
Immunization: pneumococcal vaccine and seasonal influenza vaccine
Patient education
Self-monitoring and symptom recognition
Daily weight check
Weight gain > 2 kg within 3 days: consult the doctor
Monitoring of potential side effects (e.g., hypotension caused by ACE inhibitors, hyperkalemia caused by aldosterone-antagonists, sensitivity to sunlight caused by amiodarone)
Treat any underlying conditions and contributing comorbidities.
Drugs that improve symptoms: diuretics and digoxin (significantly reduce the number of hospitalizations)!
CAPTION
OVERLAY
Definition

What is AMBOSS?

AMBOSS is an all-in-one digital resource for medical educators, students, and clinicians.

Elements of AMBOSS

Knowledge Library

- Over 1200 clinical articles
- Over 20,000 searchable medical topics
- Thousands of high-quality and interactive medical images, illustrations, videos, and charts

Question Bank

- Over 5800 ready-to-use clinical case-based questions in 5 difficulty levels
- All questions and answers linked directly to our Knowledge Library for easy cross-referencing

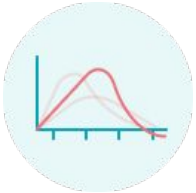

Analysis Tools

- Built-in learning analytics for personalized study plan
- Performance analysis for learning suggestions and peer group comparisons

“

AMBOSS is like UpToDate and Osmosis had a baby, and **Wikipedia raised it.**

Anonymous medical student

Our story in milestones



Founded in Germany as a study app for medical students

95% of German medical students prepare for exams using AMBOSS

Physician platform goes live in Germany

First university licenses are set up

English student platform goes live

First 10 Hospitals licenced AMBOSS

Global reach across 170 countries

English Physician platform goes live

More than 300 Clinic licenses in Central Europe

At a glance

Rapidly growing presence across international markets

2 in 3

US students studied with AMBOSS in 2021

2 Mil

Registered users worldwide

170

Countries offer access to AMBOSS

Active users worldwide

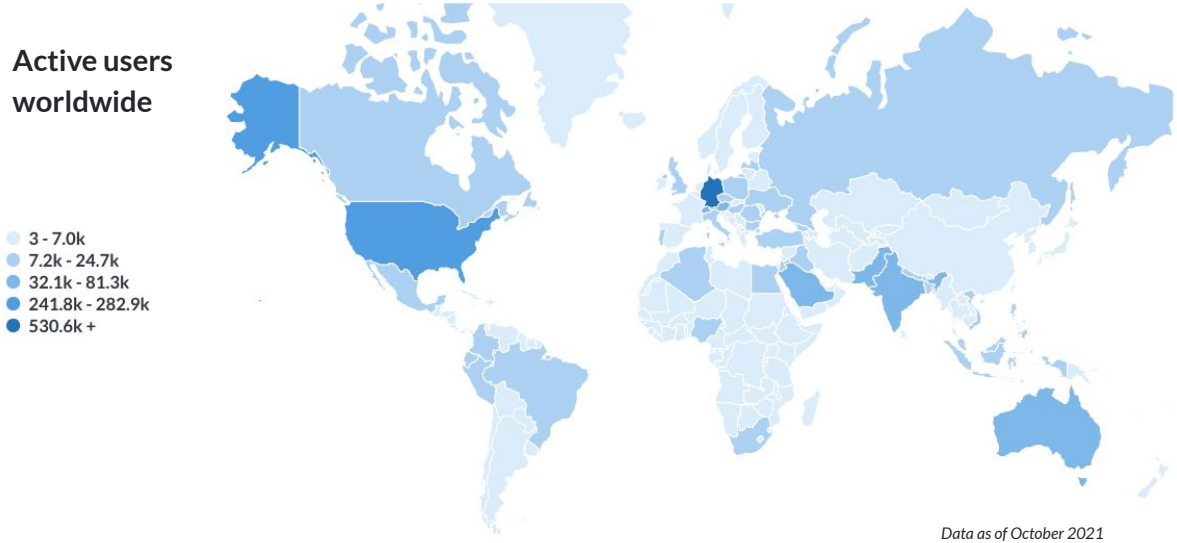

Data as of October 2021

AMBOSS

A Better Resource Leads to **Better Exam Performance**

Students who study with AMBOSS score at least 12 points higher than the national average on both USMLE® Step 1 and Step 2 CK.

The results from preliminary research and feedback directly from users indicate that medical students using AMBOSS demonstrate higher exam scores than their peers. The more students use AMBOSS, the better they perform.

This information is gathered through an ongoing survey of students. The USMLE Step 1 survey began in 2019, and the Step 2 CK survey began in 2018. Data and research remain cornerstones of AMBOSS as approaches are validated and further understanding of medical student needs is realized.

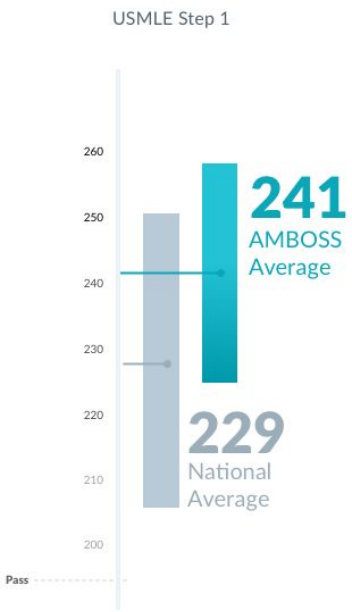

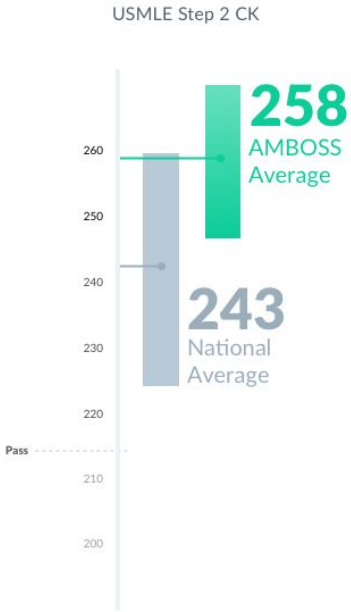

Dr. Madjid Salimi, Dr. Nawid Salimi, Benedikt Hochkirchen

“AMBOSS was founded on the vision of revolutionizing the transfer of medical knowledge, providing students and clinicians with the resources they need throughout their medical careers.”

- *Nawid Salimi*

AMBOSS Features

The Knowledge Library

How is our content created?

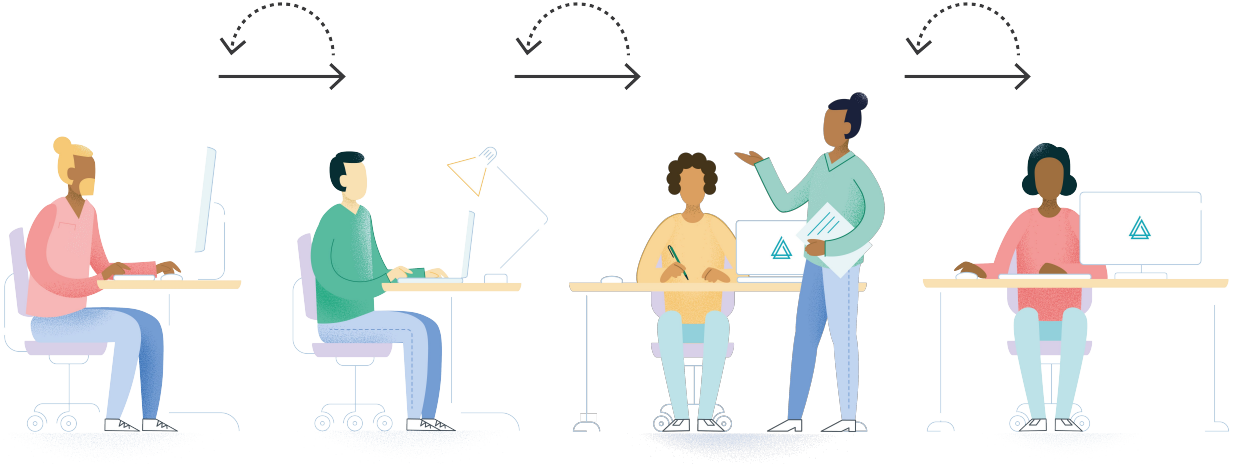

1st Physician
Content Creator

2nd Physician
Cross-Checker

Copy Editor

3rd Physician
Supervising Editor

All of our content is continuously updated by our team of over 150 physicians and language professionals.

For doctors, by doctors

Say hello to a few AMBOSS physicians.

Johanna Hase, M.D.
Physician Author

Medical school: University of Washington
Residency: NYU
Profession: Internist, Hospitalist

David S. Levitt, M.D.
Physician Author

Medical school: UCSF
Residency: University of Washington
Profession: Internist, Hospitalist

Darrell Randle, M.D.
Physician Author

Medical school: Mayo Medical School
Residency: UCSF & University of Iowa
Fellowship: Brooke Army Medical Center
Profession: Critical Care, Anesthesiologist

Emma Ruderman, M.D., M.P.H.
Physician Author

Medical school: Albert Einstein
Residency: Jacobi Medical Center
Fellowship: NYC Dept. of Health in Preventative Medicine
Profession: Internist

- Committee of medical authors includes 150 physicians and specialists
- Extensive editorial process, involving in-depth reviewreview by US-board certified physicians
- Evidence-based approach

When you buy a book, it will not update itself with the latest scientific findings!

TRANSACTIONS OF THE AMERICAN CLINICAL AND CLIMATOLOGICAL ASSOCIATION, VOL. 122, 2011

CHALLENGES AND OPPORTUNITIES FACING MEDICAL EDUCATION

PETER DENSEN, MD

It is estimated that the doubling time of medical knowledge in 1950 was 50 years; in 1980, 7 years; and in 2010, 3.5 years. In 2020 it is projected to be 0.2 years—just 73 days. Students who began medical school in the autumn of 2010 will experience approximately three doublings in knowledge by the time they complete the minimum length of training (7 years) needed to practice medicine. Students who graduate in 2020 will experience four doublings in knowledge. What was learned in the first 3 years of medical school will be just 6% of what is known at the end of the decade from 2010 to 2020. Knowledge is

AMBOSS

Browse the Knowledge Library

Users can browse the Knowledge Library by **discipline** or by **system**

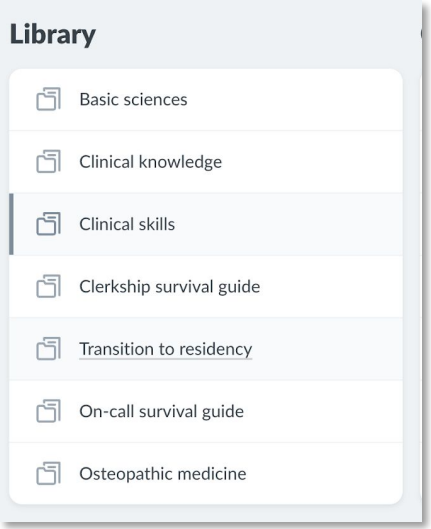

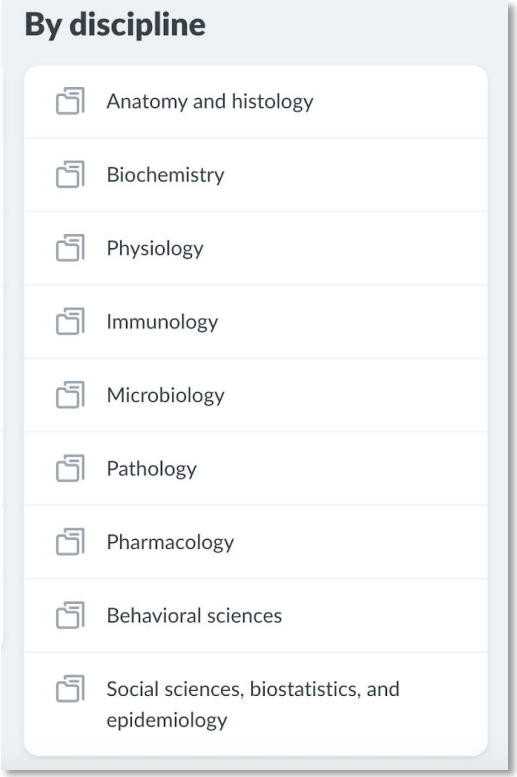

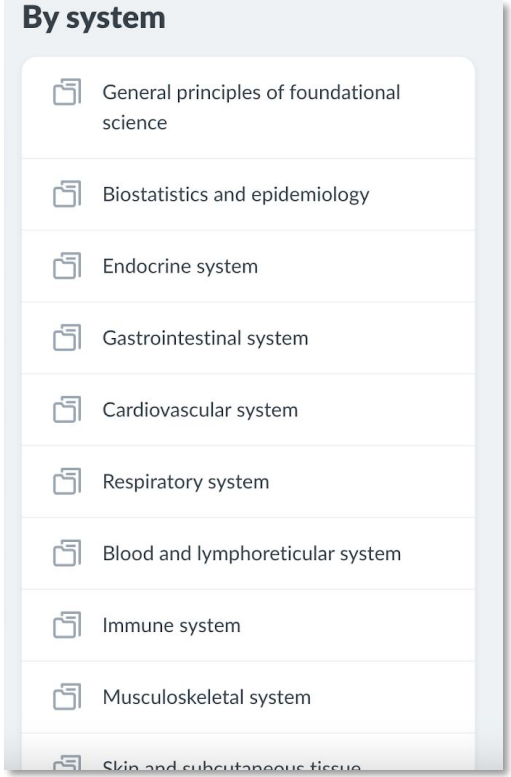

AMBOSS

Search the Knowledge Library

AI enabled search results utilizing smart search

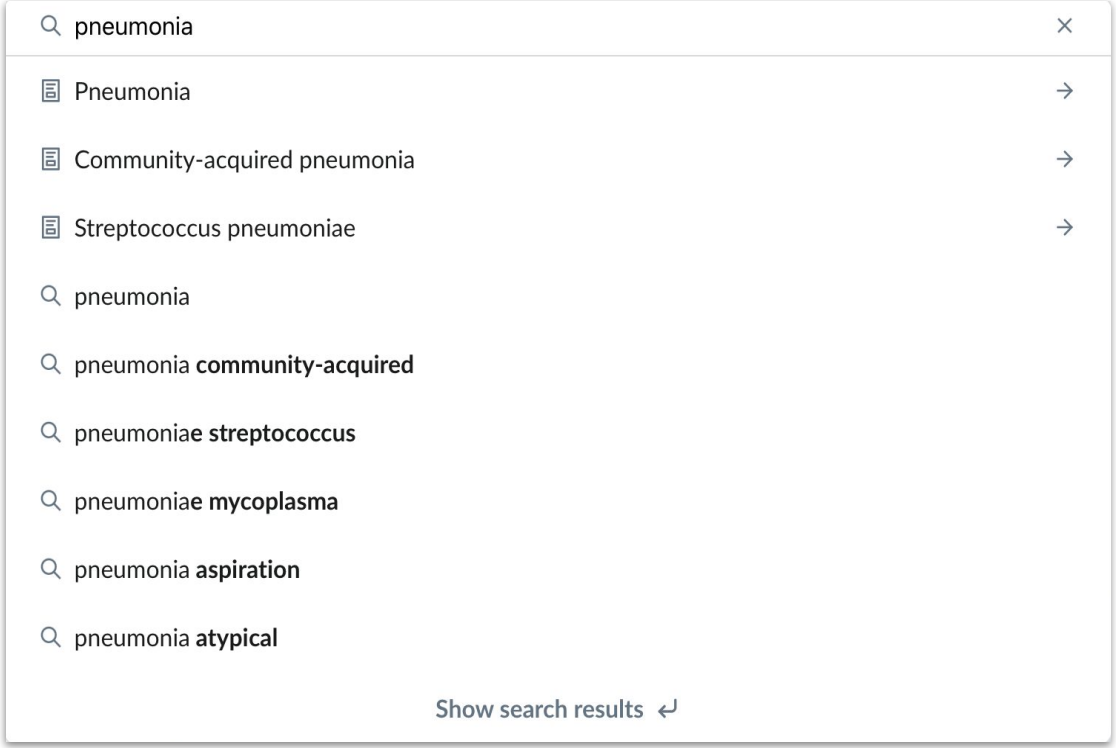

AMBOSS

Auto-linking- engine

Over 20,000 medical definitions linked to more than 1,200 articles in the AMBOSS library.

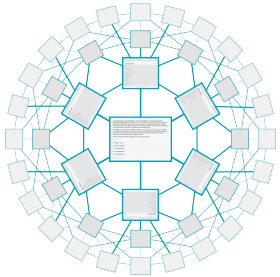

Hashimoto thyroiditis

(Hashimoto's thyroiditis, Chronic autoimmune thyroiditis) Last updated: May 04, 2020

QBANK SESSION CLINICAL SCIENCES LEARNED

Summary

Hashimoto disease is the most common form of autoimmune thyroiditis and the leading cause of hypothyroidism in the United States. Although currently thought to be due to chronic autoimmune-mediated lymphocytic inflammation of the thyroid tissue, the exact pathophysiology remains unclear. Patients are initially asymptomatic or hyperthyroid, progressing to hypothyroidism as the organ parenchyma is destroyed. Diagnosis is based on a combination of specific antibodies, thyroid function tests, and sonography of the thyroid. Treatment involves lifelong hormone replacement therapy with levothyroxine (L-thyroxine).

NOTES FEEDBACK

Epidemiology

AMBOSS

Get quick information

Users can hover their mouse cursor over a hyperlink to get quick information without losing the article. If desired, user can then click on the multimedia or the hyperlink to the new article.

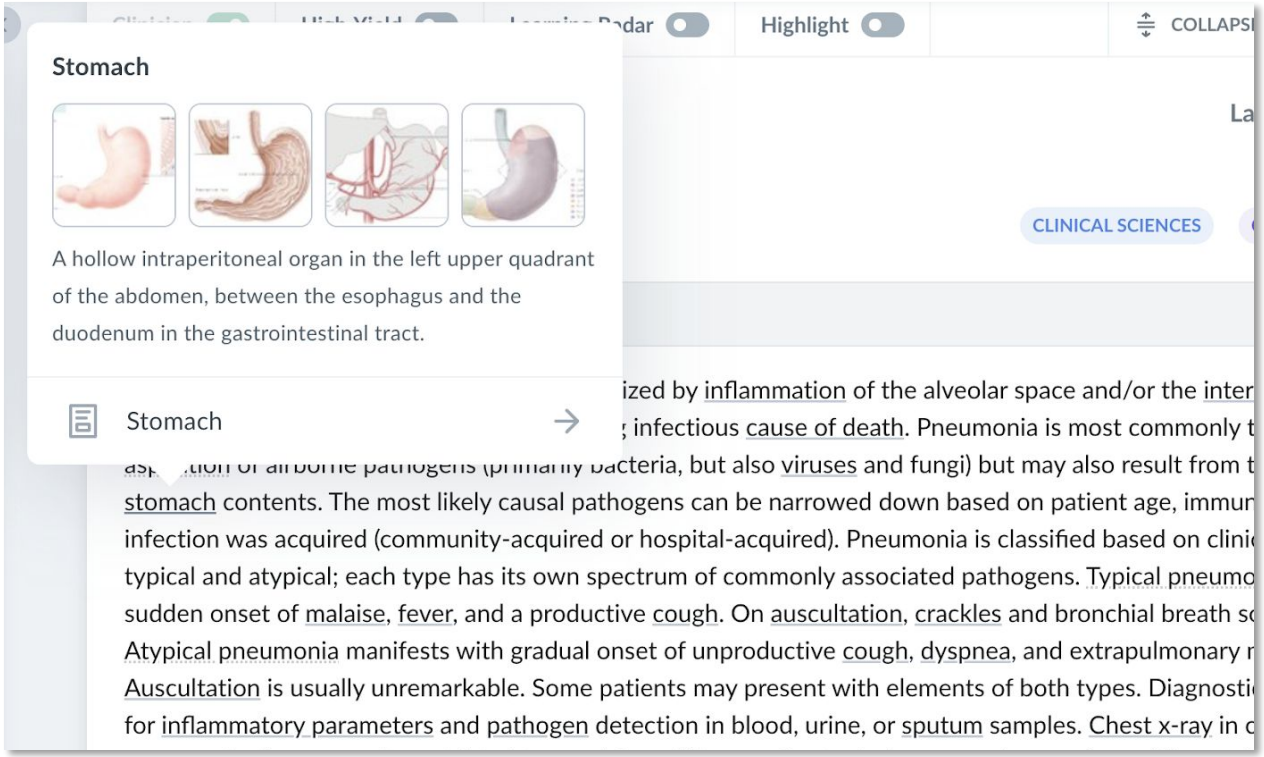

AMBOSS

Our highlighting feature helps students their their focus

The highlighting feature hones the exam-relevant skill of quickly separating the vital information from distractors.

Highlight

A 76-year-old woman with a history of hypertension and type 2 diabetes mellitus is brought to the emergency department 60 minutes after the acute onset of left-sided abdominal pain and nausea with vomiting. Three weeks ago, she underwent emergency surgical revascularization for acute left lower extremity ischemia. Physical examination shows left upper quadrant tenderness without rebound or guarding. Serum studies show an elevated lactate dehydrogenase level. Laboratory studies, including a complete blood count, basic metabolic panel, and hepatic panel, are otherwise unremarkable. A transverse section of a CT scan of the abdomen is shown. Further evaluation is most likely to show which of the following?

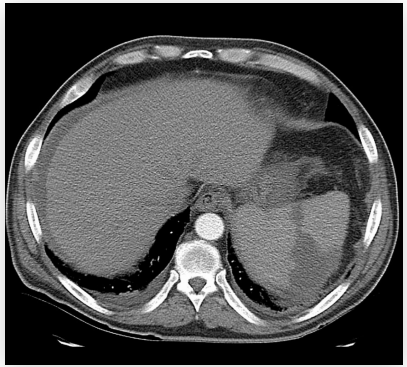

Ⓐ Absent P waves on electrocardiogram

Ⓑ Non-compressible femoral vein on ultrasonography

Ⓒ Infrarenal aortic aneurysm on abdominal CT scan

Ⓓ Right atrial thrombus on transesophageal echocardiography

Ⓔ Schistocytes on peripheral blood smear

AMBOSS

The Knowledge Library

Reference thousands of medical illustrations, images, and charts in your teaching

Illustrations

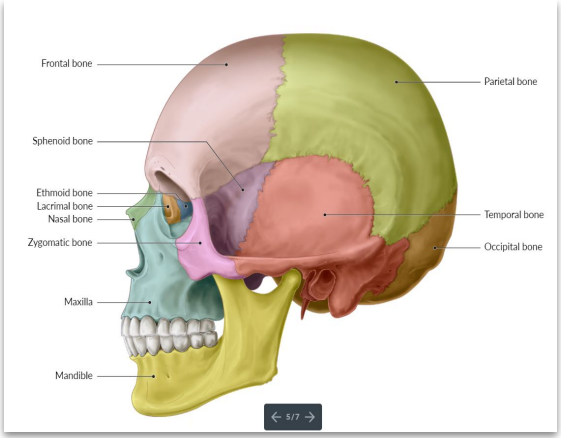

Images

Charts and Infographics

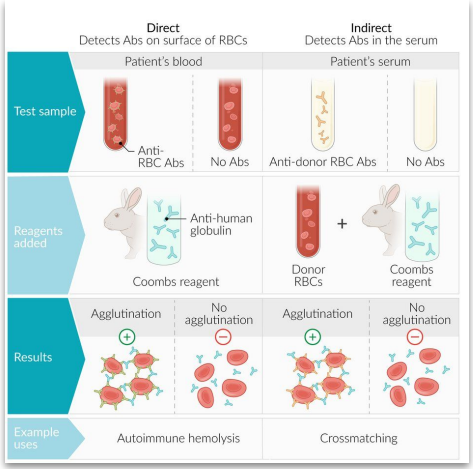

Our comprehensive collection of multimedia will help your students visualize and break down even the most complex topics.

AMBOSS

Test your students' knowledge with our built-in quizzes

Integrate table and image quizzes in your active-learning strategies to help students effectively review recent material or signpost gaps in their knowledge before moving forward.

Our quizzes can be instantly integrated into lectures or assigned to students.

MINIMIZE FINISH QUIZ

Overview

	Left lung	Right lung
Lobes and bronchopulmonary segments	• **2 lobes** (upper, lower) • Upper lobe includes the lingula, a tongue-shaped projection homologous to the middle lobe of the right lung (the rest of the space occupied by the middle lobe in the right lung is occupied by the heart in the left lung). • 8–10 bronchopulmonary segments	• **3 lobes** (upper, middle, lower) • 10 bronchopulmonary segments
Bronchi	• Left main stem bronchus is longer and more horizontal than the right bronchus • Inferior to the left pulmonary artery	
Notches		

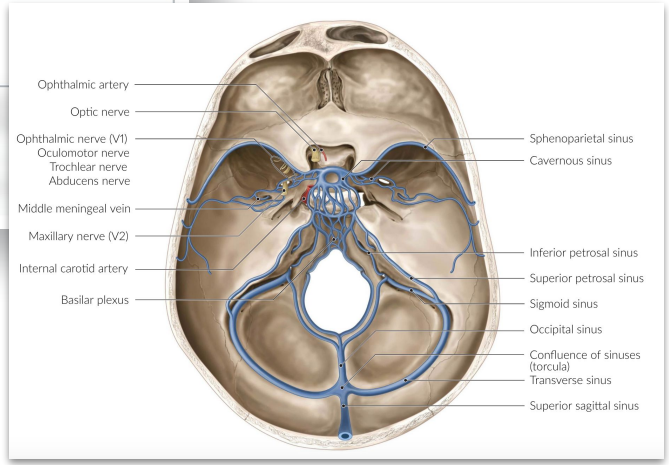

The Knowledge Library

CAPTION INDICATORS LABELS START QUIZ

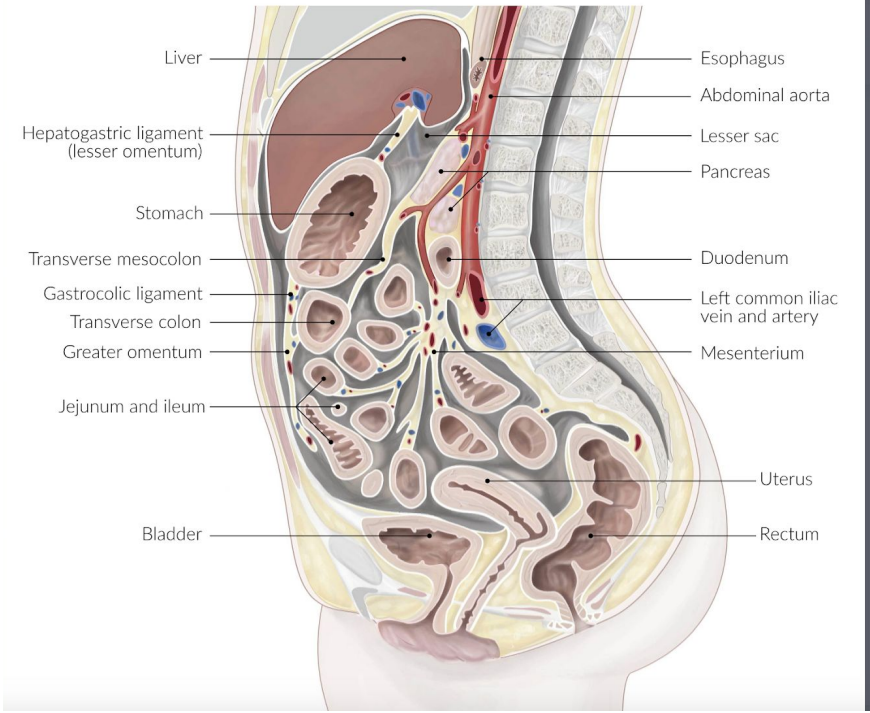

Peritoneal cavity (sagittal section)

The peritoneal cavity is the space between the parietal peritoneum, which lines the abdominopelvic cavity, and the visceral peritoneum, which invests the intraperitoneal organs. The visceral peritoneum also forms the mesentery, the greater omentum, and the lesser omentum. Intraperitoneal organs lie within the greater sac that extends from the diaphragm to the pelvis. The lesser sac (omental bursa) lies posterior to the stomach and the lesser omentum.

The Knowledge Library

CAPTION | INDICATORS | LABELS | START QUIZ

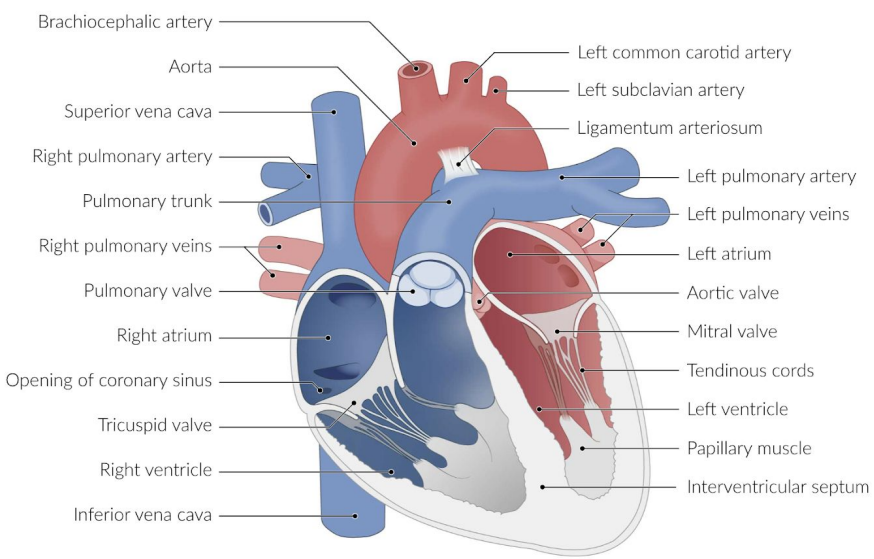

Anatomy of the heart and adjacent large vessels

Blue: structures that carry deoxygenated blood

Red: structures that carry oxygenated blood

Use our interactive medical imaging to teach

Hone your students' diagnostic skills with thousands of high-quality medical images, including radiographs, CT scans, and ultrasounds. Activate overlay to highlight particularly important or difficult to recognize features.

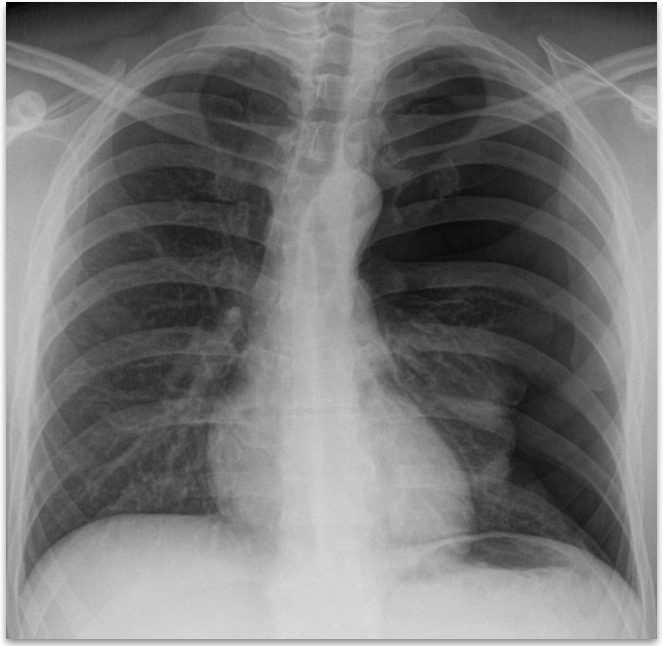

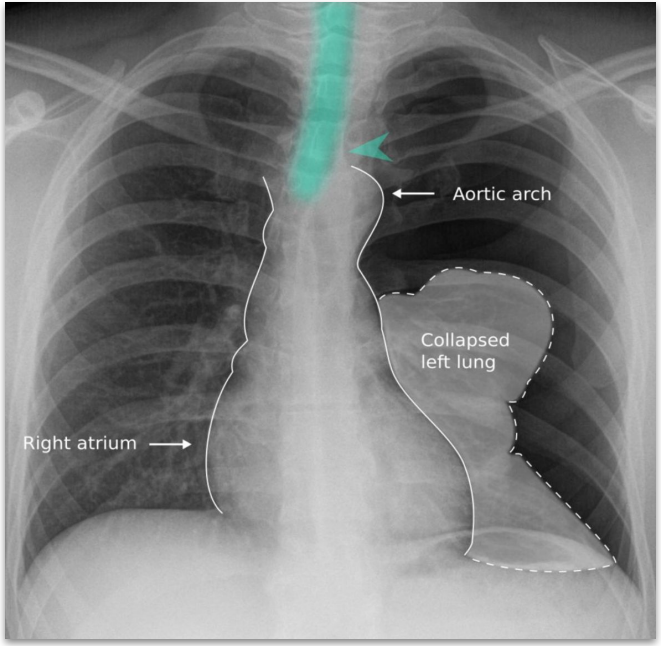

The Knowledge Library

Get the big picture with SmartZoom

Our virtual microscopy feature lets students examine annotated specimens at low to high magnification.

Ulcerative colitis

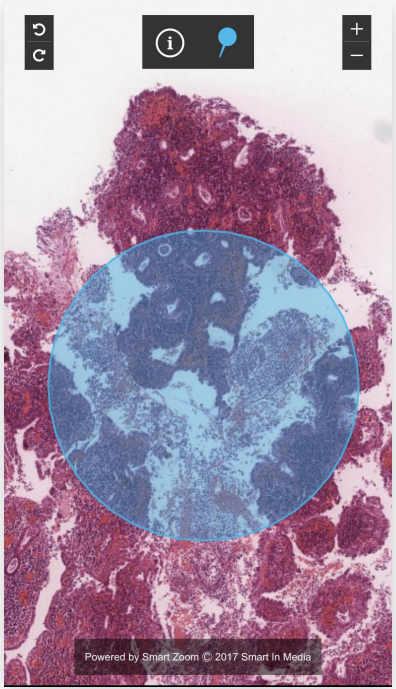

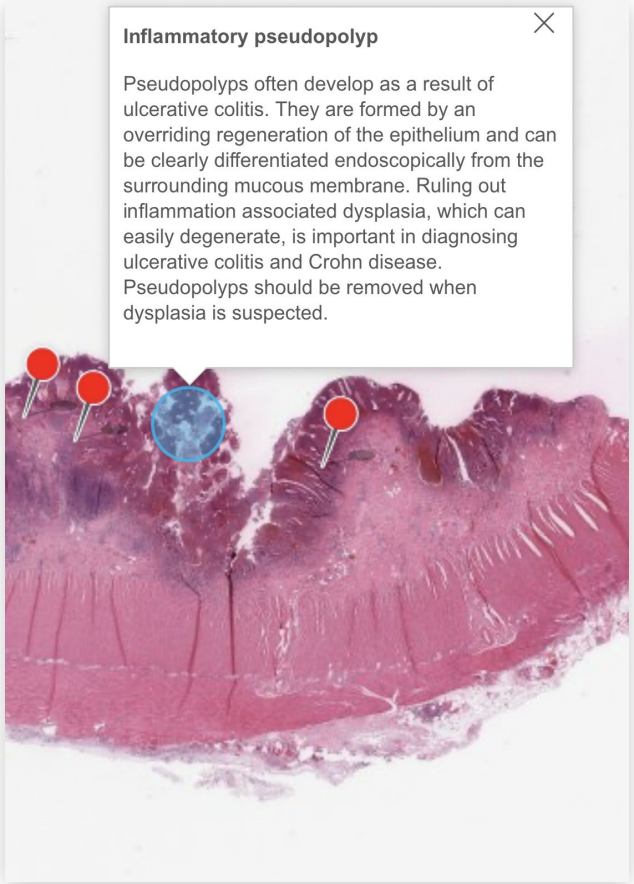

The Knowledge Library

Hundreds of expertly edited videos complement your lessons

Demonstrations of clinical procedures and ultrasound, animations of physiological functions and pathological processes, and fun tutorials underscore your didactic presentation.

Click or tap to play

The Knowledge Library

Simulate patient encounters with your students

AMBOSS

Search...

Case 1: Abdominal pain

Examinee instructions

Patient encounter

Focused history
History of present illness
Review of systems specific to recurrent abdominal pain
Past medical history, family history, and social history

Focused physical examination

Communication and interpersonal skills

Patient note

Further discussion
Patient note
Other differential diagnoses to consider

High-Yield | Learning Radar | Highlight | EXPAND ALL SECTIONS | - Aa +

Case 1: Abdominal pain

Last updated: Aug 23, 2019

LEARNED

Patient encounter

Patient instructions

- Sit hunched forward and act as if you have severe abdominal pain.
- Point at the middle and upper right part of your abdomen when the examinee asks you about the location of your pain.
- Tell the examinee that the pain is especially bad when they press on the middle and upper right part of your abdomen.
- When the examinee asks you to breathe in while they press on the upper right part of your abdomen, start to breathe in and then stop suddenly because of severe pain.
- You are not aware of the meanings of medical terms (e.g., ultrasound) and ask for clarification if the examinee uses them.
- Use the checklists below for history, physical examination, and communication and interpersonal skills.

Challenge: If the examinee mentions your weight during the encounter, act offended and say, “Are you saying I'm fat?!”

NOTES FEEDBACK

The Knowledge Library

Anki Integration

Anki flashcards help consolidate knowledge and facilitate revision.

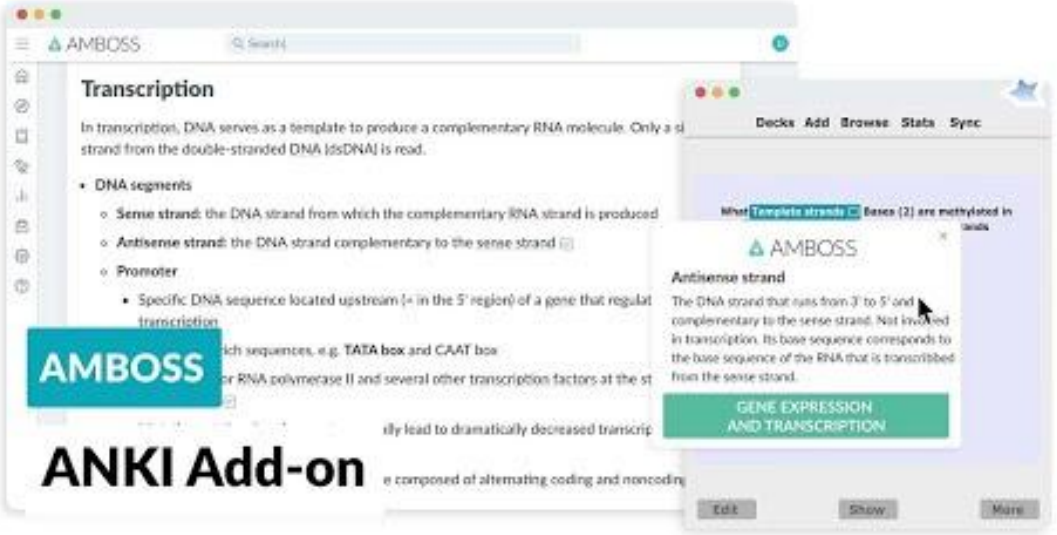

Click or tap to play

AMBOSS Features

The Question Bank

AMBOSS

The Question Bank

Use our Question Bank to assess your students' clinical knowledge

Select from over 5800 MCQs

A 62-year-old man comes to the physician because of a persistent cough for the past 2 weeks. During this time, he has also had occasional discomfort in his chest. Three weeks ago, he had a sore throat, headache, and a low-grade fever, which were treated with acetaminophen and rest. He has a history of hypertension and hyperlipidemia. His father died of myocardial infarction at the age of 57 years. He has smoked a pack of cigarettes daily for the past 40 years. Current medications include enalapril and atorvastatin. His temperature is 37°C (98.6°F), pulse is 70/min, and blood pressure is 145/90 mm Hg. Physical examination shows no abnormalities. An x-ray of the chest is shown. Which of the following is the most appropriate next step in management?

» Feedback

Ⓐ Esophageal manometry

Ⓑ CT scan of the chest

Choose the difficulty level

Difficulty

We assign each question a difficulty by using hammers, with 1 hammer meaning least difficult and 5 the most.

DONE

Customize your question sessions

- Exam
- Systems
- Symptoms
- Discipline
- Articles
- Saved questions, organized by folder

Key Info underlines the most important information.

This feature will highlight information in the question text that helps understand the focus of the question. The purpose of the Key Info feature is not only to guide but also to help you get accustomed to recognizing important information in a question, especially when starting your exam preparation.

A 68-year-old man comes to the physician because of a 4-month history of bad breath and progressive difficulty swallowing solid food. Physical examination shows no abnormalities. An upper endoscopy is performed and a photomicrograph of a biopsy specimen obtained from the mid-esophagus is shown. Which of the following is the most likely explanation for the biopsy findings?

KEY INFO | ATTENDING TIP | LABS | ADD NOTES | MARK | SAVE | SHARE | GIVE FEEDBACK

A. Well-differentiated neoplastic glandular proliferation
B. Atrophy and fibrosis of the esophageal smooth muscle
C. Metaplastic transformation of esophageal mucosa
D. Neoplastic proliferation of squamous epithelium
E. Eosinophilic infiltration of the esophageal walls

The Question Bank

The Attending tip motivates students to find the answer before frustration takes hold.

The attending tip puts students' train of thought on the right track without giving away the answer, thereby training logical reasoning and its application to differential diagnosis.

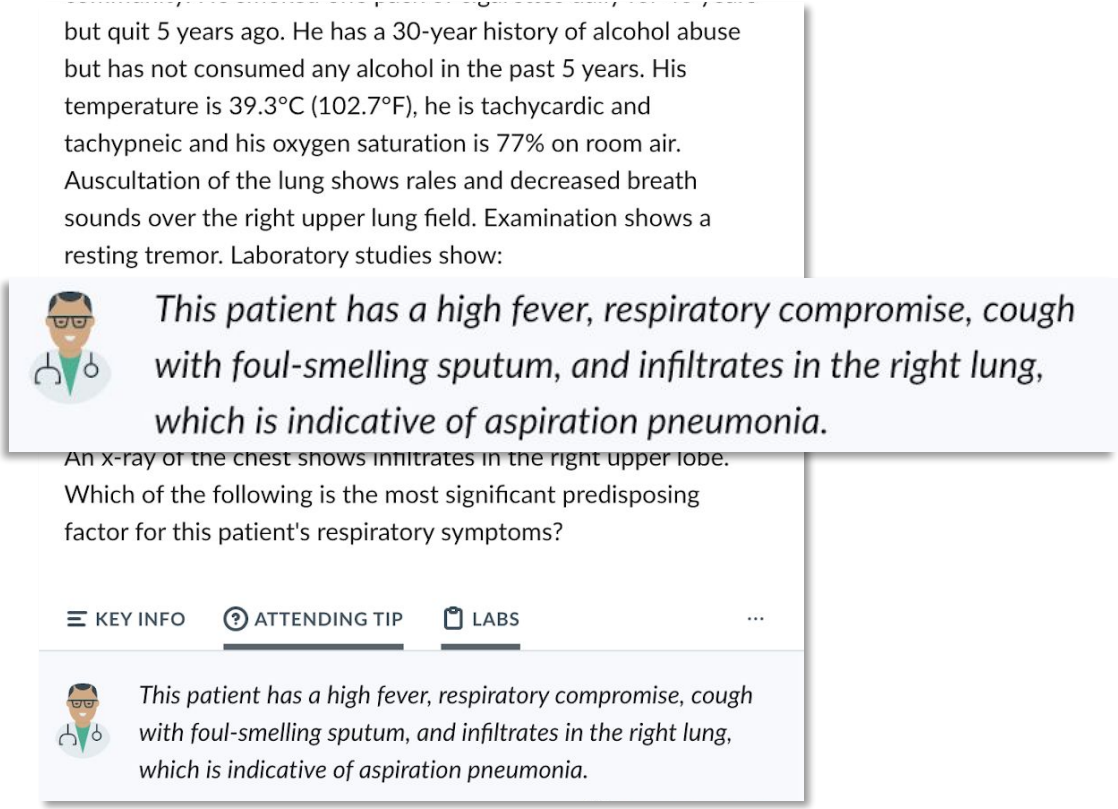

The Question Bank

Right or wrong, there's always an explanation

Every answer is annotated to illustrate the thought processes behind picking the wrong answer as well as choosing the right one.

Hyperlinks to relevant sections in the Library allow students to promptly review and dive deeper into the subject matter.

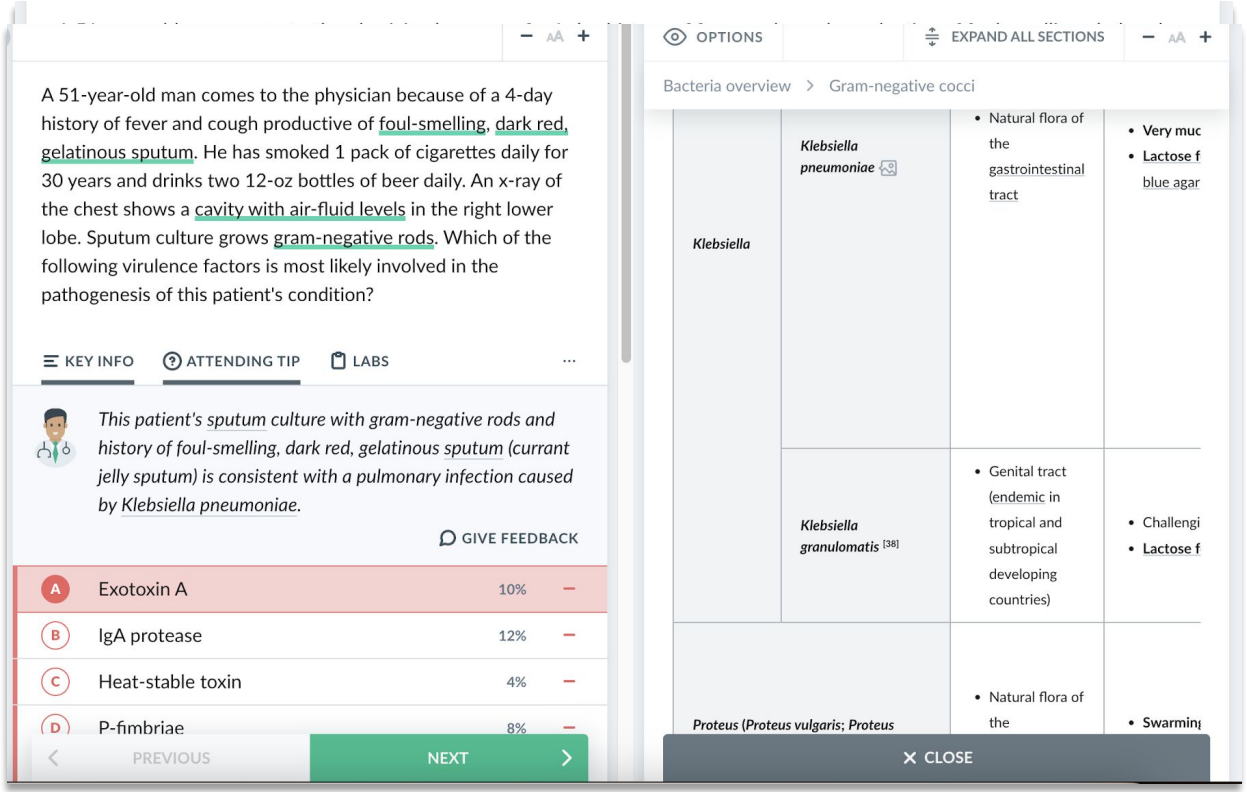

The Question Bank

Exam Mode

The Exam mode is designed in a way to simulate your exam. It has the same design and features that you have access to on the day of your USMLE/Shelf exam, so that you get accustomed to the layout and where everything is located in advance.

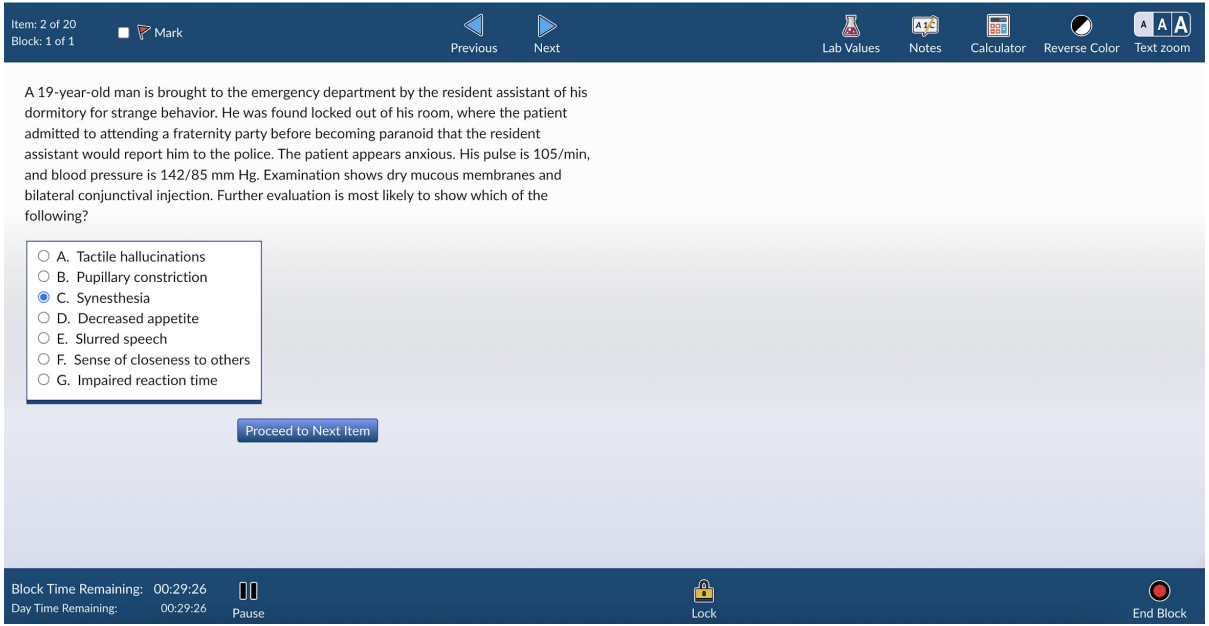

The Question Bank

Learning Radar is a great example of the integration between Knowledge Library and QBank

Pinpoints your weak areas by underlining info from the questions you got wrong in the QBank.

Learning Radar

Pathogenesis

1. Failure of protective pulmonary mechanisms (e.g., cough reflex, mucociliary clearance, alveolar macrophages)
2. Infiltration of the pulmonary parenchyma by the pathogen → interstitial and alveolar inflammation
3. Impaired alveolar ventilation → ventilation/perfusion (V/Q) mismatch with intrapulmonary shunting (right to left)
4. Hypoxia due to increased alveolar-arterial oxygen gradient
   - Hypoxia is worsened when the affected lung is in the dependent position, as perfusion to the dependent lung is better compared to the nondependent lung.
   - In the case of a large unilateral pulmonary abscess, it may be helpful to position the patient so that the affected lung is in the dependent position in order to prevent the pus from filling the unaffected lung.

Pattern of involvement

- **Lobar pneumonia**
  - Classic (typical) pneumonia of an entire lobe; primarily caused by pneumococci
  - Characterized by inflammatory intra-alveolar exudate, resulting in consolidation
  - Can involve the entire lobe or the whole lung

MAXIMIZE TABLE TABLE QUIZ

Stages of lobar pneumonia

Stages	Macroscopic findings	Microscopic findings

Learning Analytics

Students stay on track with our learning analytics.

Each student can chart their progress with our built-in learning analytics. They also receive personalized study recommendations to keep them on track.

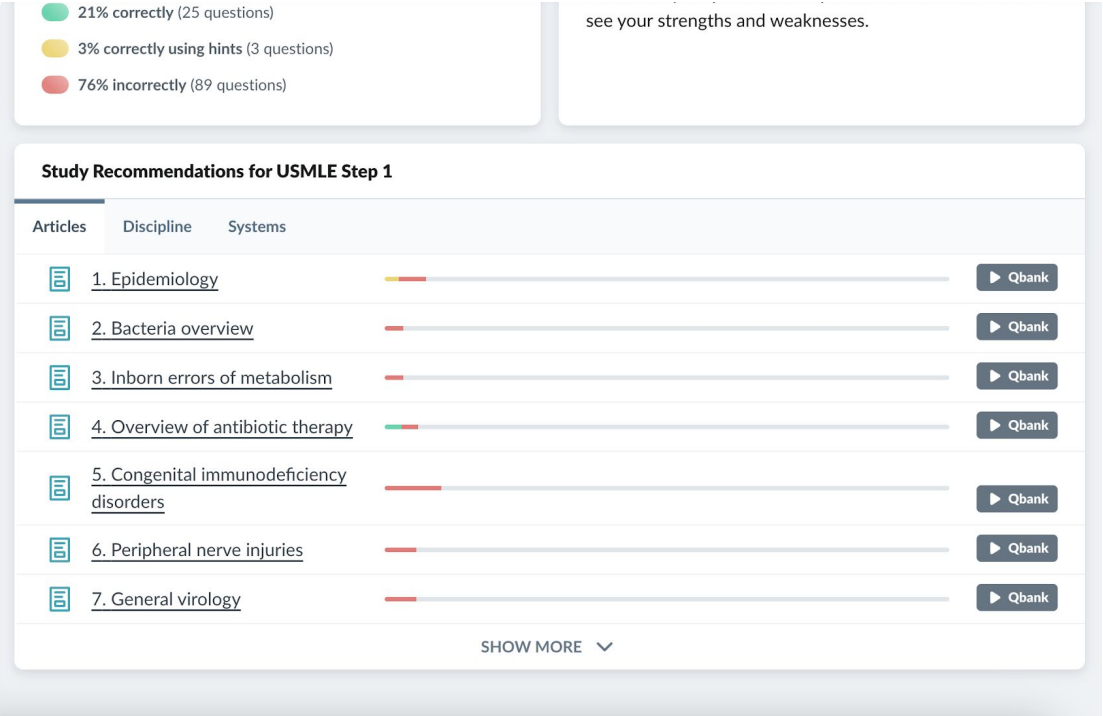

Study Planner

Study Plans allow you to study in an organized way and to easily follow a certain schedule.

Study Plans include several pre-made exam blocks broken down by system. Another option is to create your own Custom Study Plan directly in the Study Plans section.

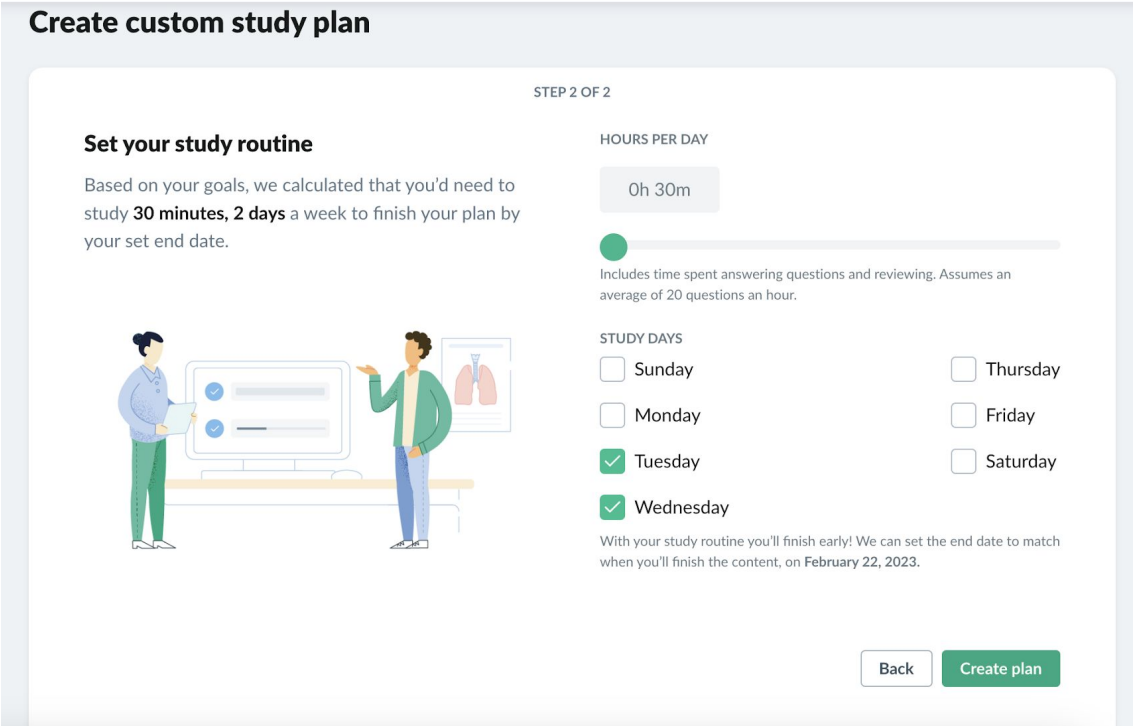

AMBOSS Features

How Instructors Can Get Involved

The Knowledge Library

Enhance the curriculum by assigning specific articles and sections to your students

next.amboss.com/us/article/fI0kXh#vR1AKg0

AMBOSS

Pneumonia

Summary

Etiology
Pathogens
Risk factors

Classification
Etiology
Location acquired
Clinical features
Area of lung affected by the pathology

Pathophysiology
Routes of infection
Pathogenesis
Pattern of involvement

Clinical features
Typical pneumonia
Atypical pneumonia

Diagnostics
Laboratory studies
Imaging
Advanced diagnostics

Treatment
Criteria for hospitalization
Criteria for ICU admission
Empiric antibiotic therapy for community-

Clinician | High-Yield | Learning Radar | Highlight | EXPAND ALL SECTIONS

Pneumonia

Last updated: Mar 23, 2022

QBANK SESSION | CLINICAL SCIENCES | CLINICIAN | LEARNED

Summary

Etiology

Classification

Pathophysiology

Clinical features

Typical pneumonia

Typical pneumonia is characterized by a sudden onset of symptoms caused by lobar infiltration.

- Severe malaise
- High fever and chills
- Productive cough with purulent sputum (yellow-greenish)
  - Crackles and bronchial breath sounds on auscultation
  - Decreased breath sounds
  - Enhanced bronchophony, egophony, and tactile fremitus
  - Dullness on percussion
- Tachypnea and dyspnea (nasal flaring, thoracic retractions)
- Pleuritic chest pain when breathing, often accompanying pleural effusion
- Pain that radiates to the abdomen and epigastric region (particularly in children)

Suspect bacterial pneumonia in immunocompromised patients with acute high fever and pleural effusion.

The Question Bank

Create and assign unique question sets with our University Sessions feature

Choose from over 5800 questions

Place them in an individual folder

Your students can find them under “My University”

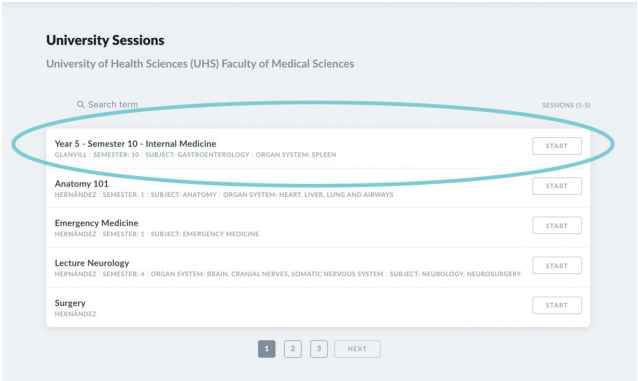

View our step-by-step tutorial here.

AMBOSS

Visualize the impact of your teaching

Our powerful learning analytics allow faculty to analyze the learning and engagement of the students, identify gaps in knowledge, and adjust the teaching.

After following date

838	364.8k	435	81%	2,585	185
Student Reach	Questions Answered	Questions per Student	Answered Correctly	Hours spent on Questions	Minutes Spent per Student

Questions Answered

Session Title	Questions per session	Questions Completed	Students Active	Average Questions / Student	Average Final Answer Correct (n) / Student	Average First-Answer Correct (n) / Student (
KBC 1: Cardiology 1	12	3,690	283	9	63%	60%
KBC 1: Cardiology 2	12	2,632	229	10	62%	60%
KBC 3: Gastroenterology & Hepatology	11	2,352	201	9	59%	56%
KBC 2: Respiratory	11	2,308	195	10	63%	60%
KBC 2: Neurology & Gerontology	18	2,169	177	10	73%	73%
KBC 4: Nephrology	19	1,691	144	10	64%	65%
KBC 3: Haematology	21	1,646	156	9	52%	52%
KBC 4: Endocrinology	11	1,343	119	9	57%	57%

Here's what some of our institutional partners have to say:

"Without a doubt, AMBOSS is a very effective and appealing platform, well worth becoming more widely known and adopted."

Prof. Dr. Gian Battista Parigi, MD, FEBS
General Coordinator, Virtual Practical Evaluative Traineeship
Faculty of Medicine, University of Pavia, Italy.

"To support the development of our students into highly qualified specialists through the elaboration of independent and critical thinking, scientific reasoning, and reasonable judgement, one of the e-learning tools TMA uses is AMBOSS."

Maia Zarnadze MD, PhD
Associate Professor, Department of Microbiology and Immunology
Co-Head of Medical Education Programmes
Petre Shotadze Tbilisi Medical Academy

"It is important to me, as an e-resource specialist, that AMBOSS has fantastic customer support with open-minded experts. They found a solution that suits our university best, despite specific and non-standard requirements."



Lucie Panchártek Suchá
eResources Specialist, Charles University Central Library

Contact us anytime!

Universities around the world choose us to stay ahead with providing medical education and supporting self-directed learning.

Empower doctors of tomorrow, together.

institutions@amboss.com

https://www.amboss.com/int/institutions